Complications of Acute Rhinosinusitis

David S. Boisoneau, M.D.

Ear Nose and Throat Associates of Southeastern Connecticut

Immediate Past President, CT State ENT Society

Clinical Adjunct Assistant Professor, QU PA Program

david@boisoneau.org

10/20/2016

RIVER VALLEY AMBULATORY SURGERY CENTER

LAWRENCE + MEMORIAL

WATERFORD 1946 MYSTIC

EAR NOSE & THROAT ASSOCIATES OF SECT

My Background

- East Ca
  Manche
- Univers
- Univers
  of Medi
- Univers
  Reside
- Ear, No
  of Southeastern Connecticut

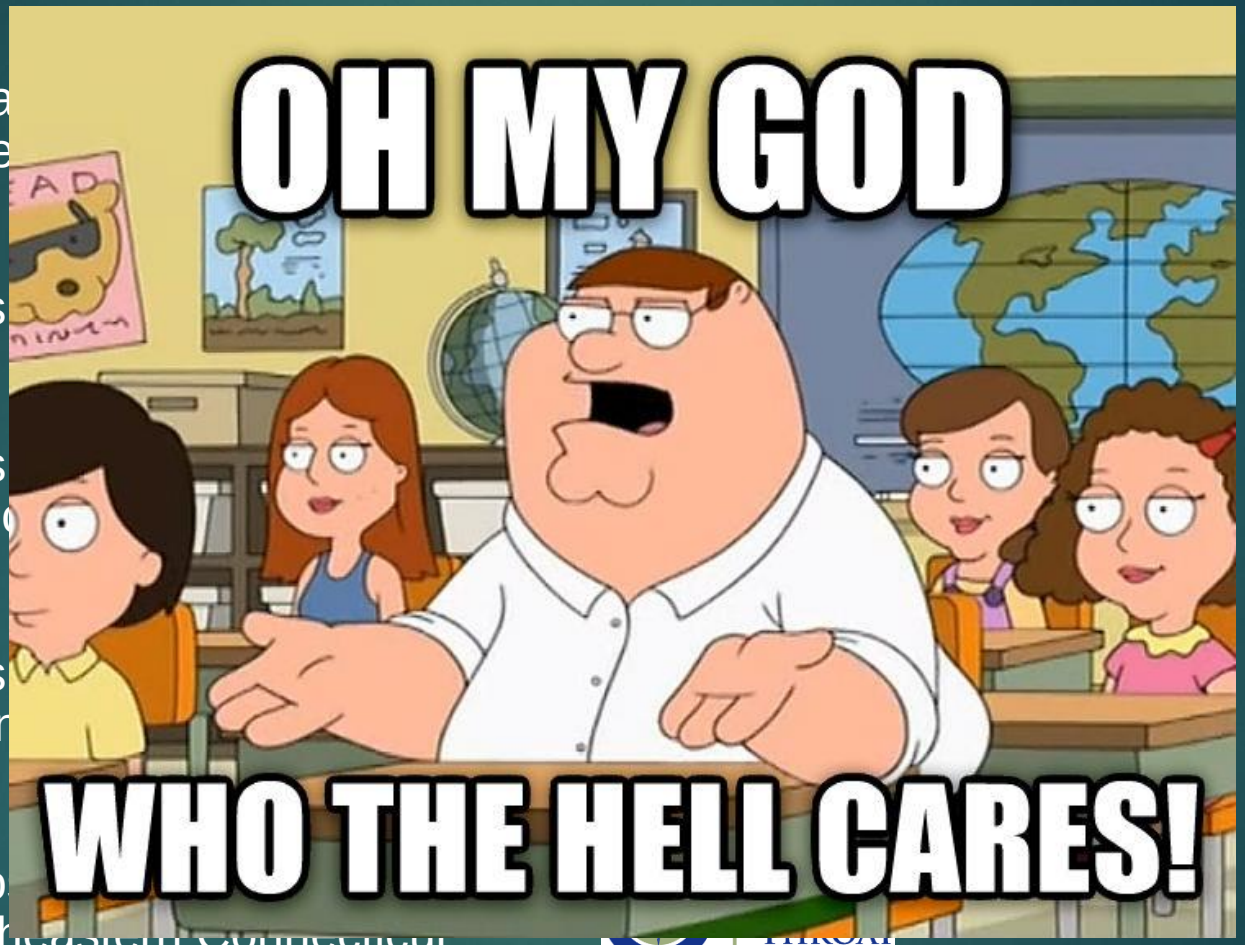

Objectives:

- Define acute rhinosinusitis
- Describe the three main types complications of acute rhinosinusitis
- Define risk factors, anatomical routes of extension and typical findings in patients suspected of complicated rhinosinusitis
- Review the medical/surgical management of the complications of acute rhinosinusitis

So what is Rhinosinusitis?

- Inflammation of the nasal mucosa and lining of the paranasal sinuses
  - Obstruction of the sinus ostia
  - Impaired ciliary transport
- Acute (up to 4 weeks)
- Chronic (greater than 12 weeks)
- Recurrent Acute (up to 4 episodes/year)

- Effects 1 in 8 adults in the U.S.
- 30 million annual diagnoses
- Direct costs exceed $11 Billion
  - Lost work
  - Reduced job performance
  - Loss of QOL
- 5th most common diagnosis requiring antibiotic therapy

Acute Rhinosinusitis

- Up to 4 weeks of *purulent nasal discharge*
  - Cloudy or colored
  - Noted by patient or found on exam

Accompanied by:

- *Nasal obstruction*
  - Obstruction, congestion, blockage, stuffiness

And/or

- *Facial pain/pressure/fullness*
  - Anterior face or periorbital region or
  - Headache that is localized or diffuse

Paranasal sinuses: all about the OMC

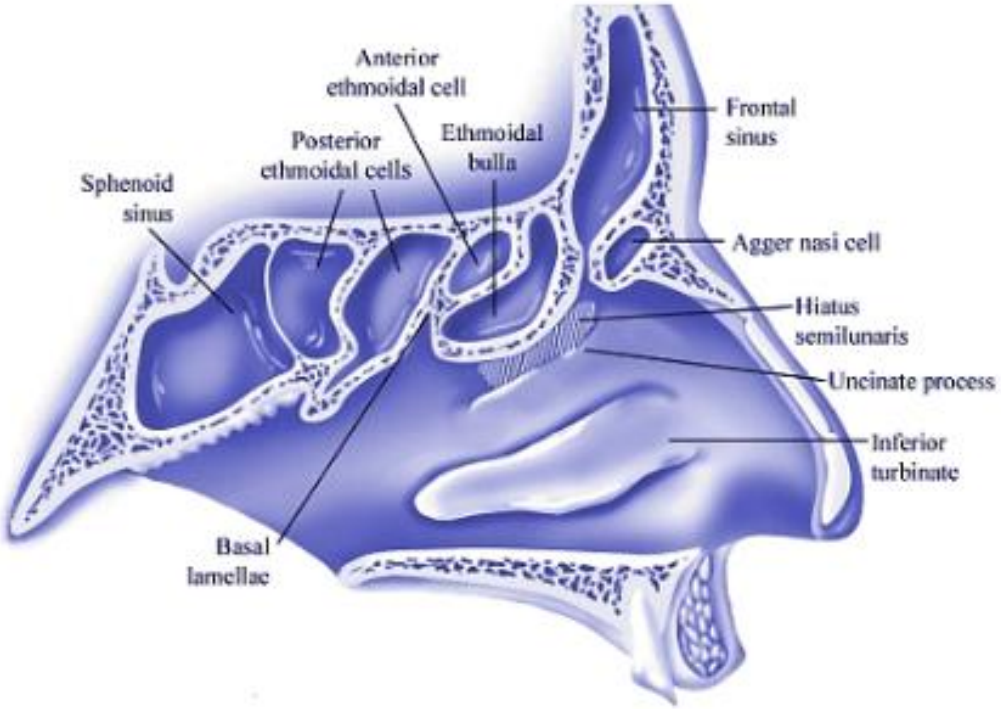

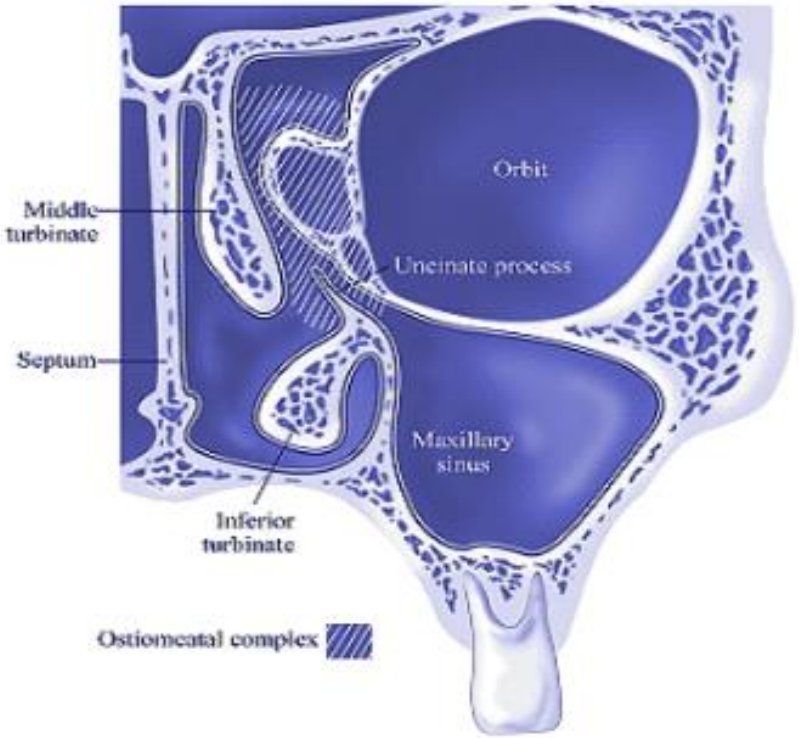

*The **ostiomeatal complex** is a common channel that links the frontal sinus, anterior and middle ethmoid sinuses and the maxillary sinus to the middle meatus that allows air flow and mucociliary drainage.*

Sinus pathophysiology in a nutshell:

Secretions thicken, pH changes

Mucosal gas metabolism changes

Cilia and epithelium are damaged

Change in host milieu creates culture medium for bacterial growth in closed cavity

Retained secretions cause tissue inflammation

Bacterial infection develops in the sinus cavity

Mucosal thickening creates further blockage

Ostium is Closed

Mucosal congestion (often due to viral rhinitis) or anatomic obstruction blocks airflow and drainage

Secretions stagnate

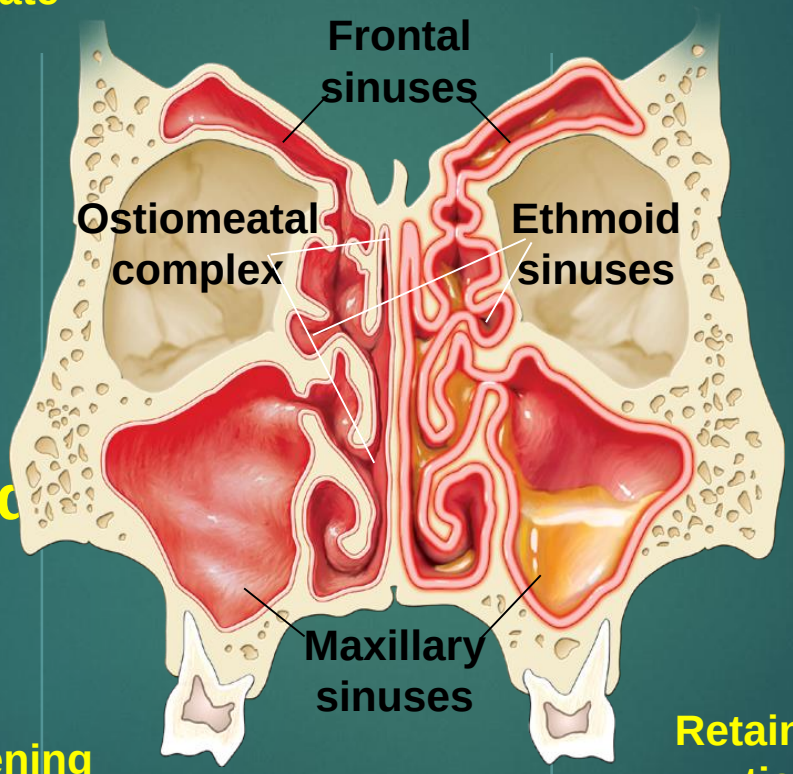

Complications of Acute Rhinosinusitis

- Complications range from relatively benign to potentially fatal
- Fortunately incidence has decreased as a result of appropriate antibiotic use
- Three main categories
  - Orbital (60-75%)
  - Intracranial (15-20%)
  - Bony (5-10%)

Imaging: CT vs MRI

CT Scan

- The established technique for patients with sinusitis
- Excellent anatomic resolution of bony details
- Best for the evaluation of orbital and bony complications

MRI

- Superior delineation of soft tissues
- Demonstrates infections without bone artifacts and brain pathology
- Best for evaluation of intracranial complications

Orbital Complications

- Most commonly involved site
  - Close proximity to ethmoid sinuses
  - Only soft tissue barrier is the periorbital/septum
  - Valveless superior and inferior ophthalmic vein
- Continuum of inflammatory/infectious changes
  - Lamina papyracea
  - Impaired venous drainage from thrombophlebitis
  - Rapid progression
- Children more susceptible
  - Higher incidence of URI's and sinusitis

Chandler's Classification for Orbital Complications

- Five classifications, can occur concurrently
  I. **Preseptal cellulitis** lid edema, no limitation in ocular motion or visual changes
  II. **Orbital cellulitis** diffuse orbital infection and inflammation without abscess formation
  III. **Subperiosteal abscess** collection of pus between medial periosteum and lamina papyracea, impaired ocular motion
  IV. **Orbital abscess** discrete pus collection in orbital tissues, proptosis and chemosis with ophthalmoplegia and decreased vision
  V. **Cavernous sinus thrombosis** bilateral eye findings and worsening of

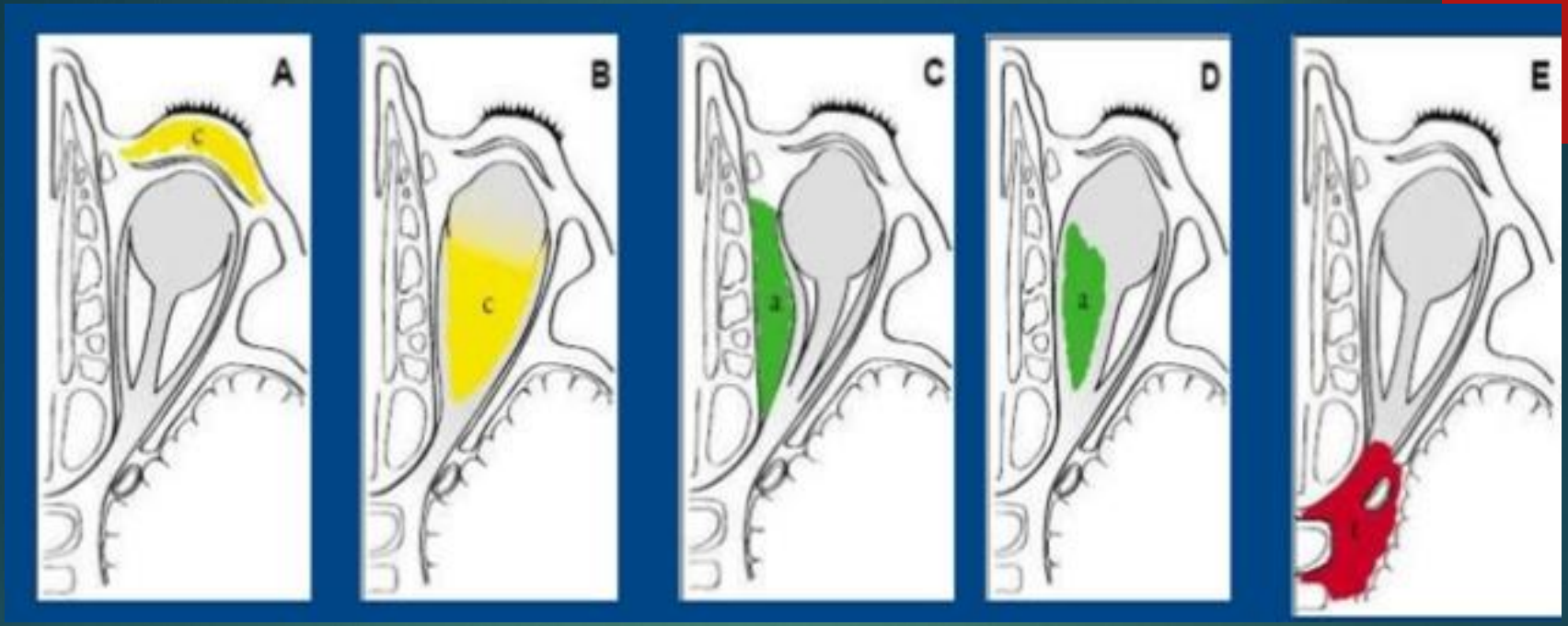
A
B
C
D
E

I. Preseptal Cellulitis

- 70% of all sinus complications
- Limited to the skin subcutaneous tissues of the eyelid, anterior to the orbital septum (normal EOM, visual acuity)
- Least severe, most frequent
- CT reveals diffuse thickening of the lid and conjunctiva

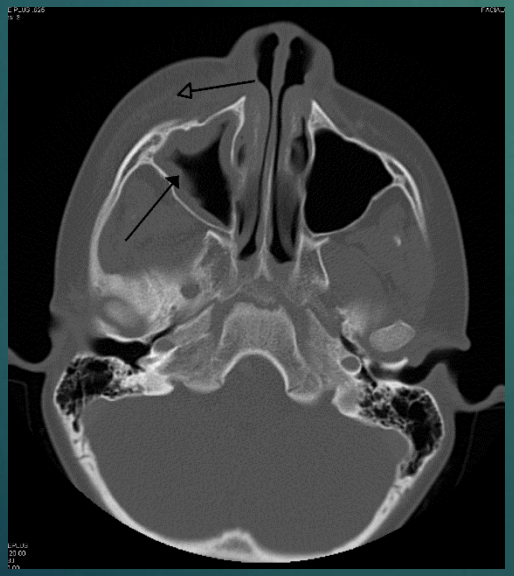

- Medical therapy usually sufficient
  - IV antibiotics
  - Warm compresses
  - HOB elevation
  - Sinus drainage

II. Orbital Cellulitis

- Post septal infection
- Eyelid edema/erythema
- Proptosis and chemosis
- Impaired EOM
- No discrete abscess
- Visual acuity intact
- CT shows low attenuation adjacent to lamina papyracea
- Same therapy as preseptal cellulitis EXCEPT may need surgical therapy in no improvement in 48 hours

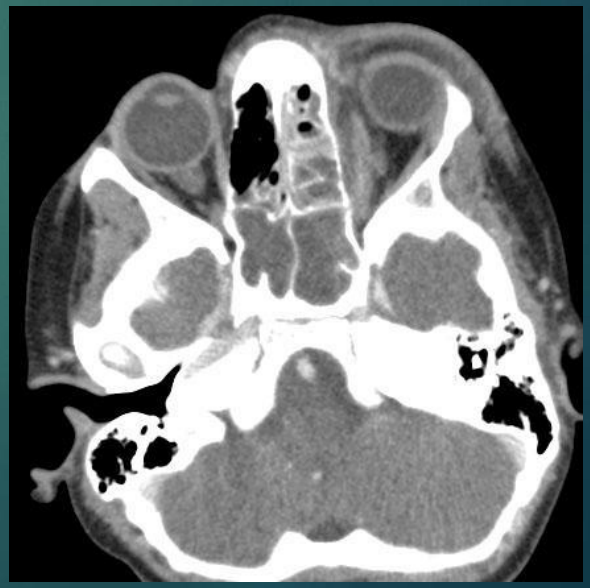

*** All surgical treatment needs to include adequate drainage of the infected sinuses*

III. Subperiosteal Abscess

- Pus formation between periorbital and lamina papyracea
- Displacement of orbital contents
- Similar presentation to orbital cellulitis but worsening proptosis and gaze restriction
- Ophthalmologic evaluation is essential
- CT shows rim-enhancing density with mass effect

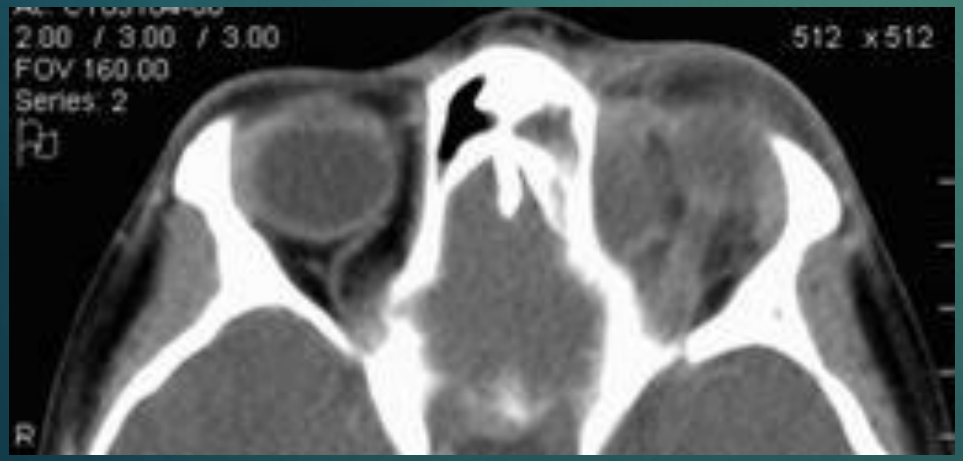

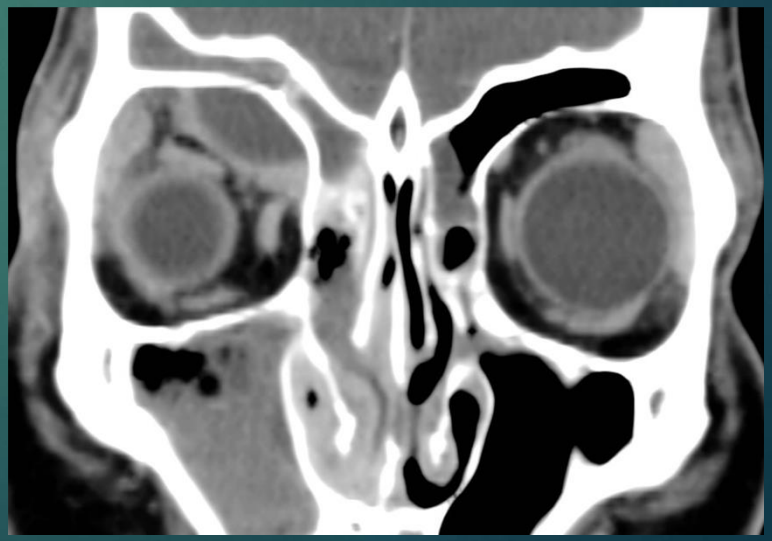

III. Subperiosteal Abscess (cont..)

- Treatment is slightly controversial
  - Medical treatment alone may be effective
  - Age <9 respond better to medical rx alone
- Reserve surgical rx for medical failures
- Open (Lynch) vs. endoscopic surgical approaches
- Primary goal of surgical treatment is to open the ethmoids and remove the lamina papyracea

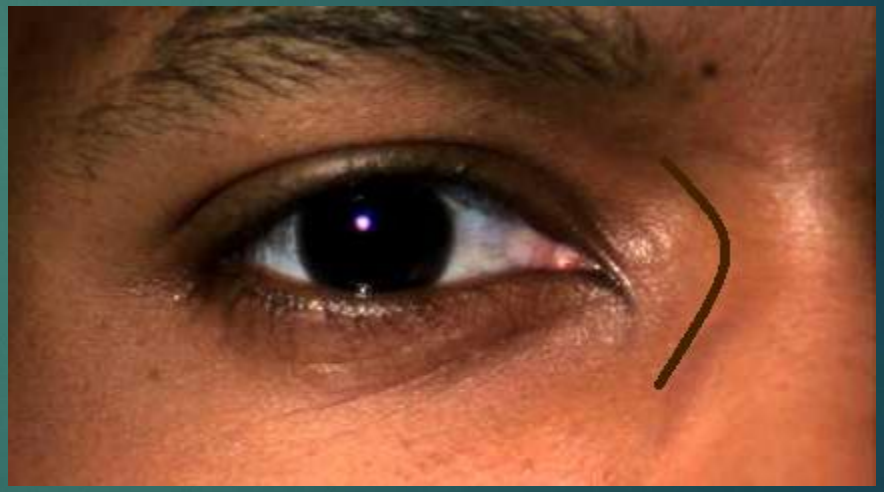

Endoscopic drainage of orbital abscess

IV. Orbital Abscess

- Pus formation within orbital tissues, inside or outside the muscle cone
  - Progression is result of immunocompromised host or delay in diagnosis
- Severe exophthalmos and chemosis
- Ophthalmoplegia
- Visual impairment
- Risk for irreversible blindness
- Can spontaneously drain through eyelid

Drainage is MANDATORY

V. Cavernous Sinus Thrombosis

- Orbital pain, proptosis and chemosis
- Spread of infection from sinuses or middle third of face
  - Freely anastomosing valveless venous system
- Symptoms in **contralateral** eye
- Associated with sepsis and meningismus
  - High morbidity and mortality (30%
  - Carotid thrombosis
- Best visualized on MRI
- High dose IV antibiotics that cross B/B barrier
- Anticoagulant use is controversial

IV. Cavernous Sinus Thrombosis

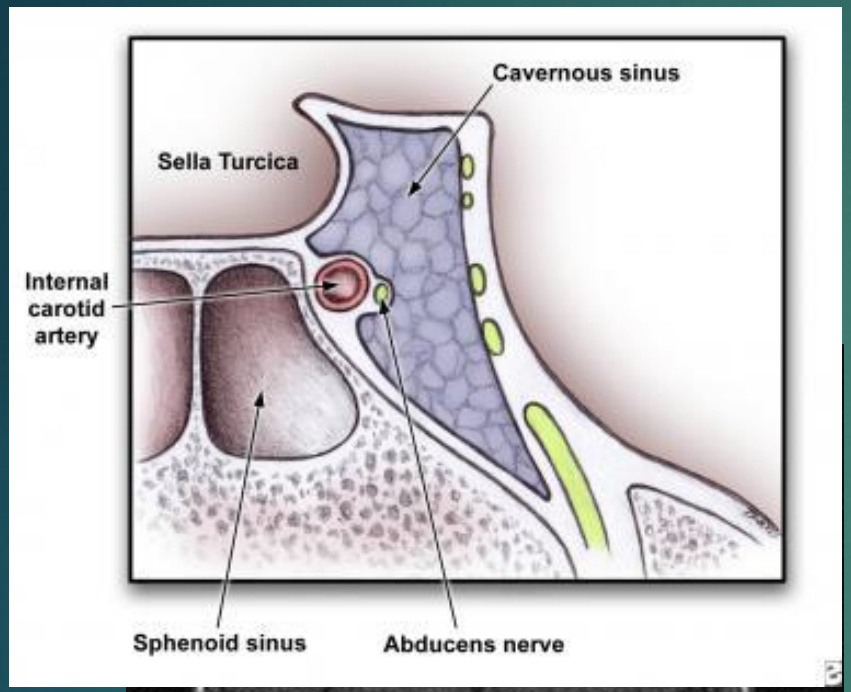

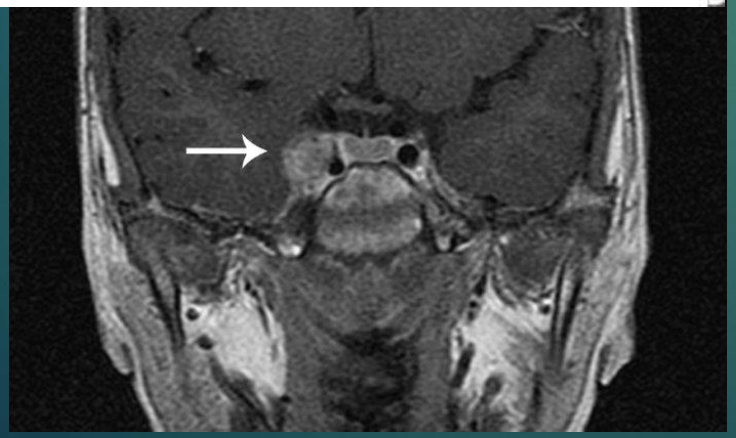

Intracranial Complications

- More common in CRS
- Direct extension
  - Sinus wall erosion
  - Trauma
  - Neurovascular foramina
- Retrograde thrombophlebitis
  - Diploic veins
  - Especially frontals
- Five main types:
  - Meningitis
  - Epidural abscess
  - Subdural abscess
  - Intracerebral abscess
  - Cavernous sinus thrombosis
- Not exclusive!

A. Osteomyelitis
B. Periorbital Abscess
C. Epidural Abscess
D. Subdural Empyema
E. Brain Abscess
F. Meningitis
G. Superior Sagittal Sinus Thrombosis

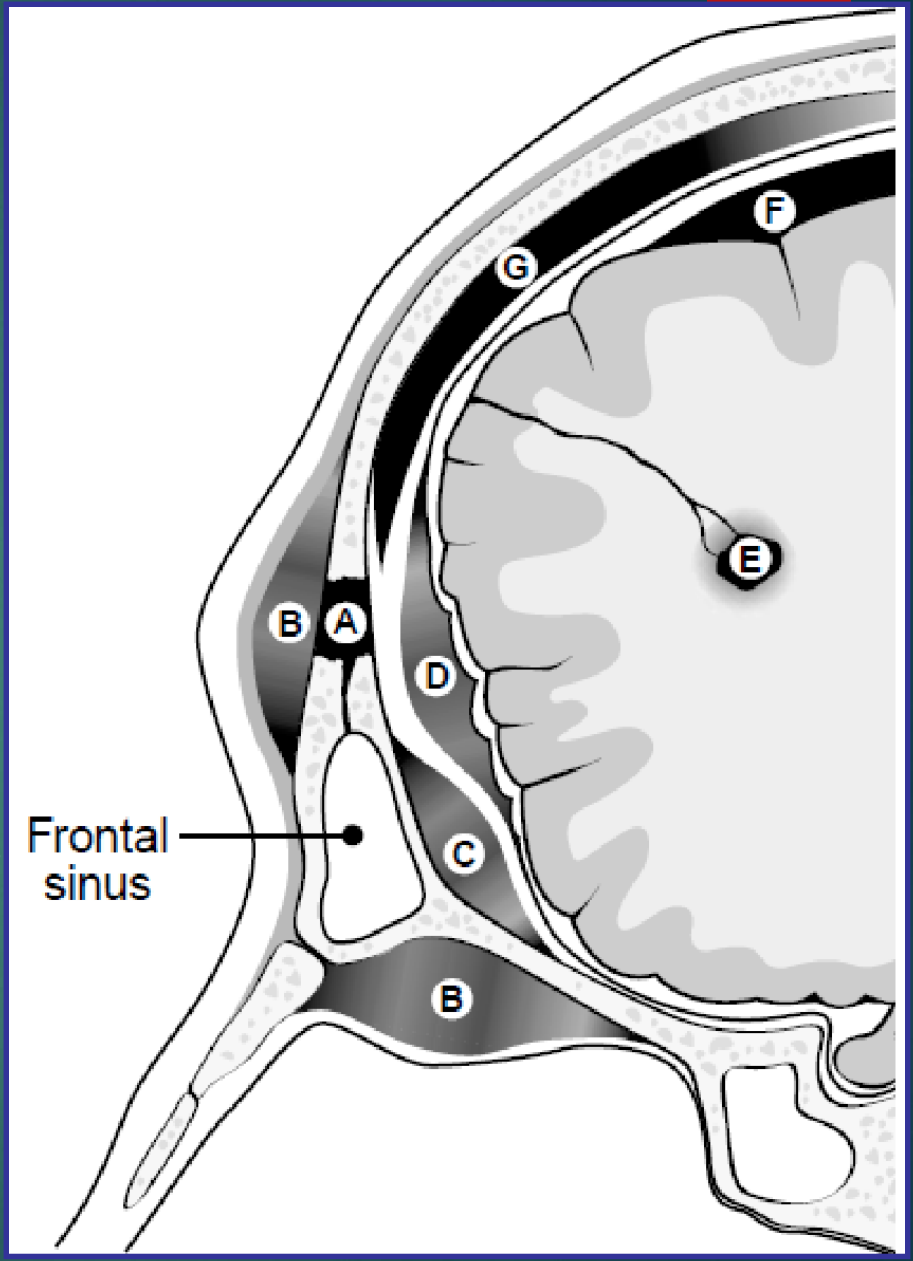

Intracranial Complications:
common signs and symptoms

- Fever (92%)
- Headache (85%)
- Nausea, vomiting (62%)
- Altered consciousness (31%)
- Seizure (31%)
- Hemiparesis (23%)
- Visual disturbance (23%)
- Meningismus (23%)

Meningitis



- Most common intracranial complication
- Sinusitis is the most common cause
  - Sphenoid
  - Ethmoids
- CT is normal, MRI may show dural enhancement
- Usually to medical treatment
  - If not better, sinus surgery may be very helpful
- Hearing loss and and seizures can be long term sequela

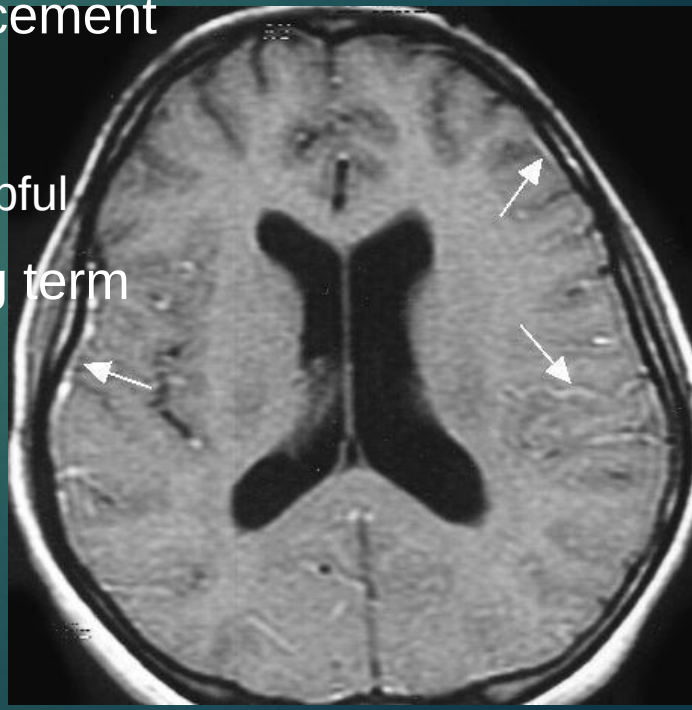

Intracranial Abscesses

	Epidural *	Subdural	Intracranial
Location	Between skull and dura	Subdural space no boundaries	Frontal/frontopariental white/gray matter
Progression	Slow expanding	Spreads diffusely convexities, interhemispheric	Asymptomatic phase while it coalesces
Symptoms	Mild, non-specific for weeks. Increase ICP	Meningismus, rapid progression to coma	Subtle if frontal (mood) H/A, lethargy, seizures, focal deficits
Diagnosis	CT or MRI	CT may show it but MRI is better	MRI (T2) Hypointense with capsule
Treatment	IV Abx. + Surgery (craniotomy / ESS)	IV Abx., craniotomy, ESS, anticonvulsivants, +/- steroids	ESS / Neurosurgery (stereotactic vs. open)

Recent OR Photo

Wellcome Images

Venous Sinus Thrombosis

- Sagittal sinus most common
- Retrograde thrombophlebitis from frontal sinusitis
- Extremely ill
  - Subdural abscess
  - Epidural abscess
  - Intracerebral abscess
- Elevated mortality rate
  - High dose abx
  - Sinus surgery
  - Anticoagulants
  - Burr holes, thrombectomy

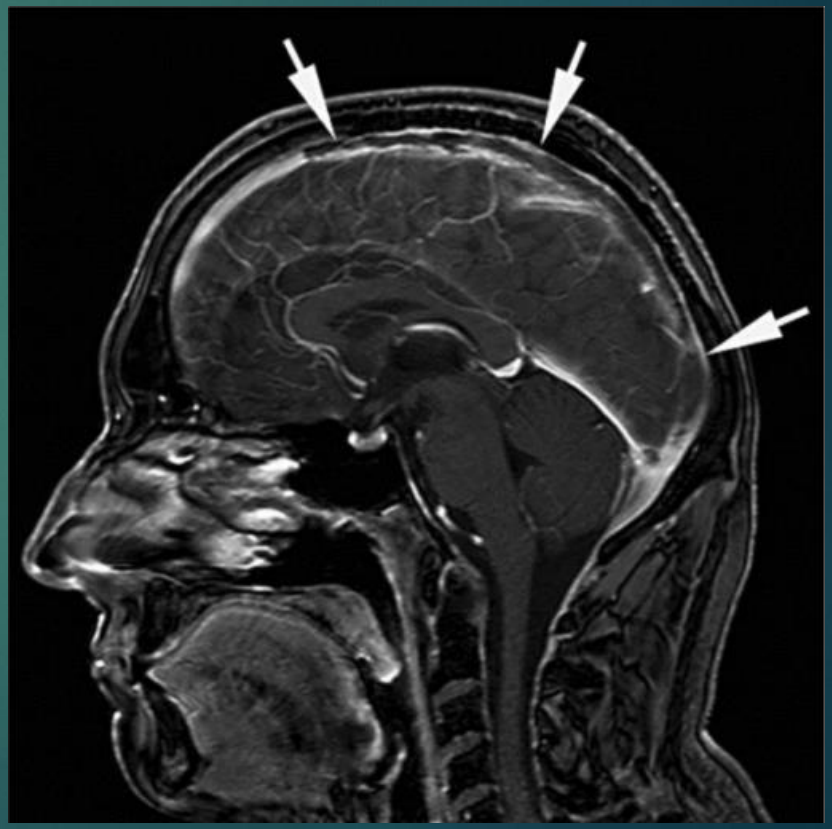

Bony Complications
(aka Pott's Puffy Tumor)

- Frontal sinusitis with acute osteomyelitis
- Subperiosteal pus collection leads to "puffy" fluctuance
- Only 20-25 cases reported in the post anti-biotic era
- Multidisciplinary team
  - ENT
  - Neurosurgery
  - Infectious disease

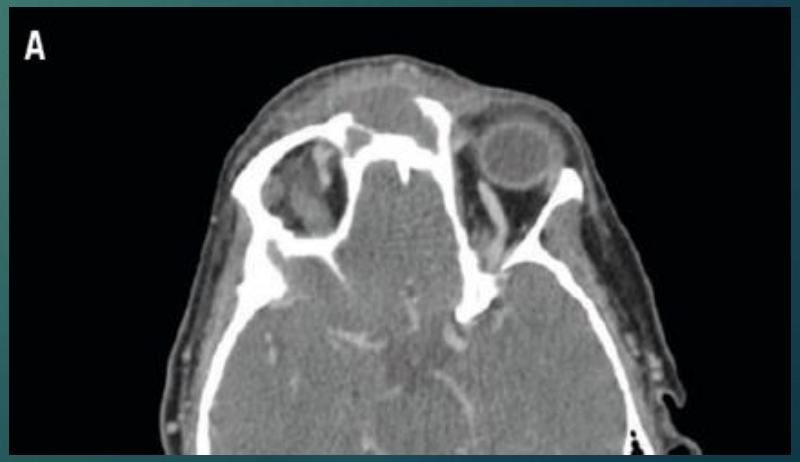

What I Learned:

(i.e. the last slide)

- Acute sinusitis is a leading cause of orbital infection, and may have other life-threatening complications
- Orbital infections may be pre or post-septal
- CT is the initial imaging modality of choice
- MRI is a valuable modality for complex intracranial cases
- Orbital & intracranial sinus complications are due to the close proximity of these structures and the presence of valveless veins.
- Children have a higher incidence of acute sinusitis and more likely to have complications
- Patients with sinusitis and persistent headache, fever, nausea, vomiting, &/or any focal neurologic abnormality should raise concerns about intracranial complications
- A team approach is essential
- Drain abscesses and open involved sinuses